

A STUDY OF INCIDENCE OF EMISSARY SPHENOIDAL FORAMEN IN DRY ADULT HUMAN SKULL BONES

Poornima B^{1*}, Phaniraj S², Mallikarjun M³

¹Assistant Professor, ² Professor, ³Professor and Head, Department of Anatomy, Vijayanagar Institute of Medical Sciences, Ballari, Karnataka, India.

ABSTRACT

Emissary sphenoidal foramen is an inconstant foramen that gives passage to an emissary vein that connects pterygoid venous plexus with cavernous sinus, the importance of which lies in the fact that an infected thrombus from an extracranial source may reach cavernous sinus. The aim of the present study was to identify the incidence of emissary sphenoidal foramen. 100 dry adult human skulls were studied which were available from the Department of Anatomy at Vijayanagar Institute of Medical Sciences, Ballari, Karnataka, India. The emissary sphenoidal foramen was present in 60 skulls out of 100 skulls studied. Out of the 60(60%) skulls, emissary sphenoidal foramen was present bilaterally in 34(34%) skulls and in the remaining 26(26%) skulls it was unilateral, 15(15%) skulls showing on right side and 11(11%) skulls showing on left side. Anatomic variations of the emissary sphenoidal foramen could be explained by developmental reasons. The anatomical knowledge of emissary sphenoidal foramen and its incidence is not only important for anatomists but equally essential for an operating surgeon.

Keywords: Emissary Sphenoidal foramen, Foramen Vesalius, Emissary veins, Cavernous sinus Thrombosis.

INTRODUCTION

The skull has numerous foramina through which neurovascular structures course. Emissary sphenoidal foramen is a small foramen located anteromedial to the foramen ovale and lateral to foramen rotundum and vidian canal [1]. This foramen is also known as foramen of Vesalius. It opens between foramen ovale and scaphoid fossa inferiorly [2]. When this foramen is present, it transmits sphenoidal emissary vein/veins connecting cavernous sinus with pterygoid venous plexus, thus communicating extracranial veins and intracranial venous sinus. Thus, septic thrombus from extracranial source can reach cavernous sinus producing thrombosis of cavernous sinus. The probable reason for this condition is the infection within the orbit and paranasal air sinuses. It can be due to infection involving upper half of the face. The condition is manifested by severe pain in the eye and forehead region due to involvement of ophthalmic division of trigeminal nerve. Trismus can occur if mandibular nerve is involved [3].

Since the literature review gives few reports, the present study was done to establish the incidence of the emissary sphenoidal foramen.

MATERIALS AND METHODS

100 dry adult human skulls were available from the Department of Anatomy, Vijayanagar Institute of Medical Sciences, Ballari, Karnataka, India. The emissary sphenoidal foramen was identified in the skulls. Its presence was noted both unilaterally, (right side and left side) and bilaterally in the skulls.

RESULTS

The emissary sphenoidal foramen was identified in 60 skulls i.e. 60% of the 100 skulls studied. Among the 60 skulls which showed the foramen, in 34 skulls it was present bilaterally on both right and left side, the incidence being 34%. sphenoidal foramen was totally absent in 40% (40) of the skulls.

In the 26 skulls, i.e. 26% foramen was unilateral, 15 skulls with 15% incidence showed foramen on right side only and 11 skulls with 11% incidence showed

foramen on left side only. The emissary sphenoidal foramen was totally absent in 40% (40) of the skulls.

Figure 1. Showing 100 dry adult human skull bones.



Figure 2. Showing presence of unilateral emissary sphenoidal foramen

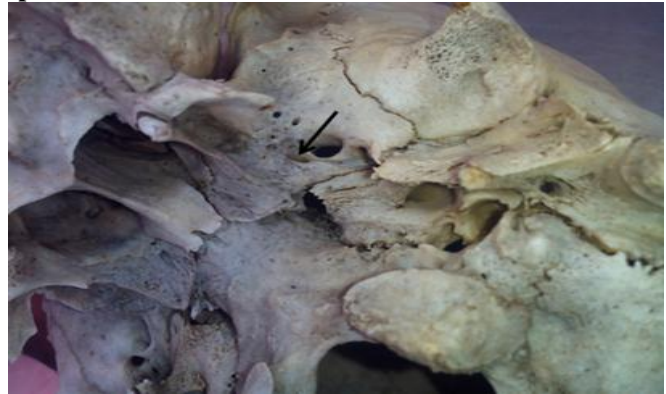
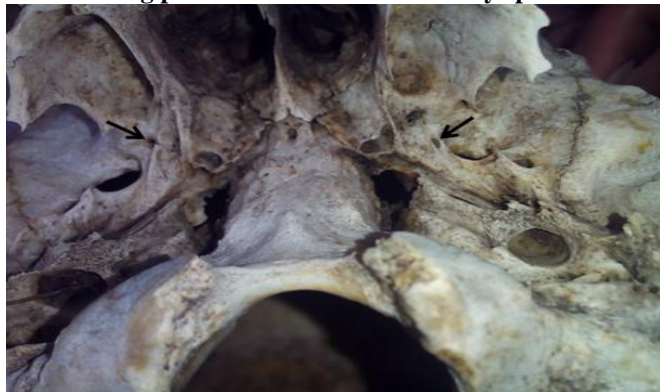

Figure 3. Showing presence of bilateral emissary sphenoidal foramen



DISCUSSION

The FV is originally found as the emissary foramen by Andreas Vesalius [4].

Development

Developmentally most of the central skull base bones are preformed in cartilage and then ossify by the process of endochondral ossification with a small contribution from membranous bone. At 11 weeks 5 days the entire skull base is preformed in cartilage and then ossification of skull base progresses in an orderly pattern from posterior to anterior. The sphenoid bone is formed by postsphenoid and presphenoid centres that appear at 14 weeks and 17 weeks respectively with a contribution from orbitosphenoid and alisphenoid centres that appear at 16 weeks and 15 weeks respectively [5]. The greater wings are formed from alisphenoid centres. Moreover, it has been shown that the foramen of Vesalius represents the site of fusion between the membrane bone and medial cartilaginous, ala temporalis [6].

Wood-Jones reports that the foramen ovale is an important venous outlet in humans. Occasionally the

venous anterior portion of the foramen ovale is constricted and elongated, or venous portion of the foramen ovale may tend to become subdivided from the nervous portion due to the in-growing spicules of bone which may cut the foramen ovale into two parts, the anterior of which may be regarded as the foramen of Vesalius or emissary sphenoidal foramen. In some cases, foramen of Vesalius lie 2 to 3 mm anteromedial to foramen ovale and this is regarded as the maximum degree of sub division of foramen ovale⁷. Hence the emissary sphenoidal foramen is an expression of the differentiation of cranial venous outlets that is characteristic of humans and does not occur in any other primate [7].

Reymond [8] reports incidence of 17% of the foramen whereas Bergman [9] reports incidence of 59%. In the studies conducted by Rossi [10] (unilateral 26.25%, bilateral 13.75%), Shinohara [11] (unilateral 18.25%, bilateral 15.5%) and Boyd [13] (unilateral 21.8%, bilateral 14.7%), whereas Ozer [12] (unilateral 25.5%, bilateral 9.3%) reports marked increase in unilateral

foramen. In the study by Gupta [1] (unilateral 20%, bilateral 22.85%), Kodama [14] (unilateral 5.5%, bilateral-16.3%) and Bergman [9] (unilateral 24%, bilateral 35%) bilateral incidences are reported more. In the studies done by Boyd [12] (left - 11.2%, right-10.6%), Kale [15] (left-10.37%, right-9.51%), Shinohara [11] (left-10.5%, right-7.75%), and Ozer [12] (left-15.1%, right-10.4%). Rossi reports increased right side incidence 15.62% compared to left side 11.25 % [10].

REFERENCES

1. Gupta N, Ray B, Ghosh S. Anatomic characteristics of foramen Vesalius. *Kathmandu University Medical Journal*, 3 (2), 2005, 155-158.
2. Nirmala D, Hema N. Study of Emissary Sphenoidal Foramen and its Clinical Implications. *Journal of Evidence Based Medicine and Healthcare*, 1(4), 2014, 175-179.
3. Freire AR, Rossi AC, Souza de Oliveria VC, Prado, Ferreira Caria PH, Botacin PR. Emissary foramina of the human skull, Anatomical characteristics and its relations with clinical neurosurgery. *Int J Morphol*, 31(1), 2013, 287-92.
4. Vesalius A. De humani corporis fabrica libri septem (Basel). Ex officina Joannis Oporini, 1543.
5. Nemzek WR, Brodie HA, Hecht ST, Chong BW, Babcock CJ, Seibert JA. MR, CT, and plain film imaging of the developing skull base in fetal specimens. *American Journal of Neuroradiology*, 21, 2000, 1699-706.
6. James TM, Presley R, Steel FL. The foramen ovale and sphenoidal angle in man. *Anat Embryol (Berl)*, 160, 1980, 93-104.
7. Wood-Jones F. The non-metrical morphological characters of the skull for racial diagnosis. Part I. General discussion of the morphological characters employed in racial diagnosis. *J Anat*, 65, 1931, 179-195.
8. Reymond J, Charuta A, Wysocki J. The morphology and morphometry of the foramina of the greater wing of the human sphenoid bone. *Folia Morphologica*, 64(3), 2005, 188-193.
9. Bergman RA, Afifi AK, Miyauchi R. Illustrated encyclopedia of Human Anatomic Variation, Opus V, Skeletal Systems, Cranium. Sphenoid bone. Accessed on 31/5/2014 <http://www.anatomyatlases.org/AnatomicVariants/SkeletalSystem/Text/VariationsSizeSymmetry.shtml>
10. Rossi AC, Freire AR, Prado FB, Caria PHF, Botacin PR. Morphological characteristics of foramen of Vesalius and its relationship with clinical implications. *J Morphol Sci*, 27, 2010, 26-29.
11. Shinohara AL, de Souza Melo CG, Silveira EM, Lauris JR, Andreo JC, de Castro Rodrigues A. Incidence, morphology and morphometry of the foramen of Vesalius, complementary study for a safer planning and execution of the trigeminal rhizotomy technique. *Surg Radiol Anat*, 32(2), 2010, 159-64.
12. Ozer MA, Govsa F. Measurement accuracy of foramen of vesalius for safe percutaneous techniques using computer-assisted three-dimensional landmarks. *Surg Radiol Anat*, 36(2), 2014, 147-54.
13. Boyd GI. The emissary foramina of the cranium in man and the anthropoids. *Journal of Anatomy*, 65, 1930, 108-121.
14. Kodama K, Inoue K, Nagashima M, Matsumura G, Watanabe S, Kodama G. Studies on the foramen Vesalius in the Japanese juvenile and adult skulls. *Hokkaido Igaku Zasshi*, 72(6), 1997, 667-74.
15. Kale A, Aksu F, Ozturk A, Gurses IA, Gayretli O, Zeybek FG et al. Foramen of Vesalius. *Saudi Med J*, 30(1), 2009, 56-59.

CONCLUSION

Emissary sphenoidal foramen is an inconsistent foramen of sphenoid bone. In our study, incidence of this foramen was 60%. The knowledge of the presence of emissary sphenoidal foramen is of great importance to the clinicians in the diagnosis and management of various conditions where micro-neurosurgical and microvascular approach at the base of the skull is required due to its variability in its incidence and its clinical implications.